

Case Report

Clinical Manifestation of Peutz-Jeghers Syndrome in Children with Gastrointestinal Bleeding: A Case Report

Yudith Setiati Ermaya¹, Dyah Rahmawanti¹, Ina Rosalina¹, Dwi Prasetyo¹

¹ Department of Child Health, Faculty of Medicine Padjadjaran University, Dr. Hasan Sadikin General Hospital Bandung, Indonesia

Corresponding author:

Yudith Setiati Ermaya, MD
yudith.ermaya@unpad.ac.id

Published:

13 May 2022

DOI:

<https://doi.org/10.58427/apghn.1.1.2022.28-34>

Citation:

Ermaya YS, Rahmawanti D, Rosalina I, Prasetyo D. Clinical Manifestation of Peutz-Jeghers Syndrome in Children with Gastrointestinal Bleeding: A Case Report. *Arch Pediatr Gastr Hepatol Nutr.* 2022(1):28-34.

Abstract: The Peutz-Jeghers Syndrome (PJS) is a rare familial disorder with manifestation that varies from asymptomatic to a life-threatening emergency. The PJS is caused by mutations of the tumor suppressor gene STK11 in embryonic cells, which is traditionally characterized by the development of melanotic macules and intestinal polyps. This case is about a boy, five years old, admitted to the emergency unit with a chief complaint of dark-red blood stool, pale appearance, abdominal pain, and nausea. Upon physical examination, there were multiple black spots on the lips and buccal mucosa (melanotic macules). Laboratory findings showed hemoglobin levels of 5.9 g/dL and a hematocrit of 18.7%. Multiple polyps at the fundus, corpus, antral, ileocecal, terminal ileal, transverse colon, sigmoid colon, and rectum were identified from the endoscopy examination. There were signs of upper and lower gastrointestinal bleeding in the pylorus of the stomach and the middle part of the descendent colon from the scintigraphy, respectively.

Keywords: children, Peutz-Jeghers Syndrome, gastrointestinal bleeding, choledochal cysts

Introduction

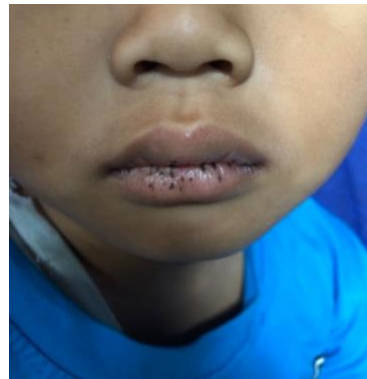Gastrointestinal polyps commonly cause lower gastrointestinal bleeding in children over one-year-old. The Peutz-Jeghers syndrome (PJS) is a polypotic hamartoma syndrome with typical mucocutaneous pigmentation. It is a rare autosomal dominant inherited disorder. PJS occurs in one in 50,000–200,000 live births and is associated with an increased risk of gastrointestinal and extraintestinal cancer. Patients usually complained of painless rectal bleeding. The PJS is characterized by hamartomatous intestinal polyps in association with a distinct pattern of skin and mucosal macular melanin deposition.^{1,2} This report aims to describe the gastrointestinal bleeding manifestation found in the pediatric PJS patients.

Case

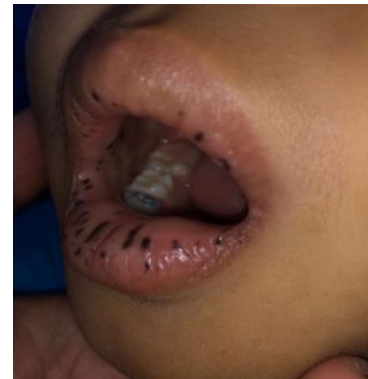A 5-year-old boy complained of dark and bloody stool, pallor, abdominal pain, and nausea. Anemic conjunctiva and multiple black spots on the lips and buccal mucosa (melanotic macules) were found upon the physical examination. Abdominal tenderness was present, especially in the epigastric area. The patient had a similar complaint prior to the current admission. He was hospitalized at a district hospital and received a red blood cell transfusion, then discharged after improvement of condition. Three days after being discharged, he complained of bloody stool. Therefore, he was referred to our hospital. His father had the same complaints but had not received further examination.



(a)



(b)



(c)

Figure 1. Physical examination (a) Dark Stool. (b) Melanotic macules on Lips. (c) Melanotic macules on buccal of a child with Peutz-Jeghers syndrome.

Upon laboratory findings during emergency admission, the hemoglobin level was 5.9 g/dL, the hematocrit 18.7%, leukocyte $9,540/\text{mm}^3$, and the platelet count $756,000/\text{mm}^3$. He was diagnosed with anemia due to gastrointestinal bleeding. He received transfusion therapy, but his hemoglobin level further declined during hospitalization due to the recurrence of bloody stool. The laboratory findings of the subjects are described in **Table 1**.

Table 1. Laboratory finding of the subject.

Parameters	Unit	Day 1	Day 2	Day 7	Day 8	Day 15	Day 18
Hemoglobin	(g/dL)	5.9	9.5	8.8	11.9	8.1	9.2
Hematocrit	(%)	18.7	30.1	27.2	35.8	24.3	28.3
Leukocyte	(/mm ³)	9,540	8,980	5,850	8,290	7,240	6,910
Platelet	(/mm ³)	756,000	572,000	582,000	538,000	696,000	648,000
PT	second	-	-	-	11.60	-	-
aPTT	second	-	-	-	21.50	-	-
INR	-	-	-	-	1.60	-	-
AST	(U/L)	-	-	-	28	19	-
ALT	(U/L)	-	-	-	25	20	-

Notes: PT = prothrombin time; aPTT = activated partial thromboplastin time; INR = international normalized ratio; AST = aspartate aminotransferase; ALT = alanine aminotransferase.

Endoscopy and colonoscopy were performed. **Figure 2** showed the description and results of the endoscopy and colonoscopy examinations. The black bloody stool was identified from the terminal ileum upon endoscopy examination.

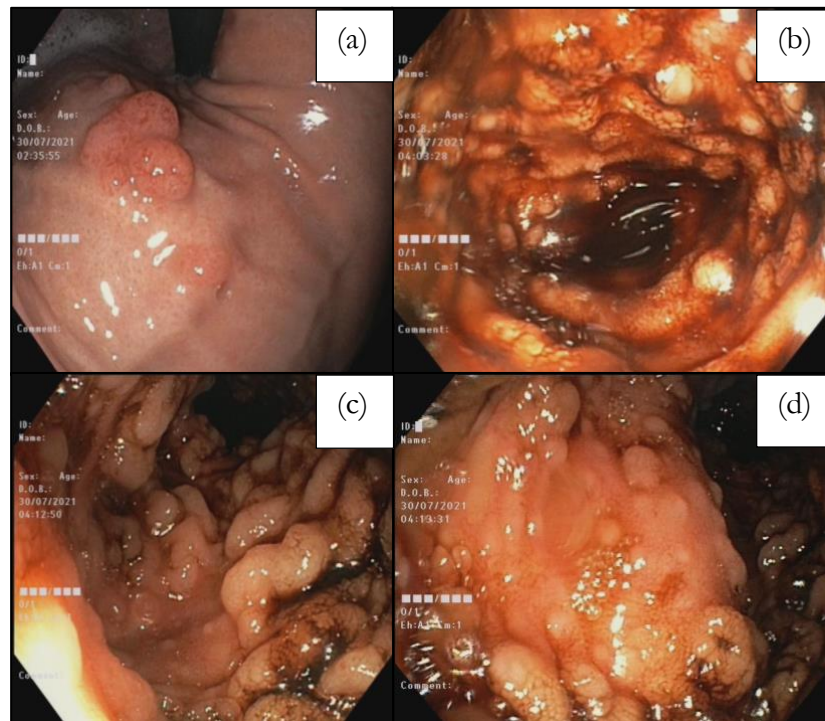


Figure 2. Endoscopy and colonoscopy of upper gastrointestinal tract. (a) Multiple polyps dominated by gastric fundus and corpus. (b) Multiple rectal polyps. (c) Multiple transverse colon polyps. (d) Multiple terminal ileal polyps.

Upper gastrointestinal tract endoscopy showed esophagitis, erosive gastro-duodenitis, multiple polyposis, multiple scar ulcers in the region of the duodenal bulb, bile reflux, and antral hypoperistalsis. Lower gastrointestinal tract colonoscopy showed colitis, ileitis, cryptitis, and multiple polyposis. A biopsy was performed on all sections. Hyperplastic polyps were found in the fundus, corpus, antral, ileocecal, terminal ileal, transverse colon, sigmoid colon, and rectum.

A gastrointestinal scintigraphy examination was subsequently performed to identify any potential bleeding sites that could not be visualized by endoscopy. Technetium injection was used for scintigraphy (**Figure 3**). The scintigraphy showed signs of upper gastrointestinal bleeding in the gastric pylorus and lower gastrointestinal bleeding in the mid descending colon. The gastric pylorus showed pathologically increased radioactivity from the planar imaging and single-photon emission computed tomography (SPECT) during the fifth minute that became more apparent over time. During the 120th minute, pathologically increased radioactivity appeared in the mid descending colon at the third lumbar vertebra level which became clearer and began to progress toward distal projection over time. No radioactivity was seen in other parts of the body.

The patient was also consulted to the pediatric surgeon and planned for surgical bleeding control with combined colonoscopy and laparotomy exploration. However, the patient's family refused to undergo the operation. Although the patient still had a bloody stool, he was discharged from the hospital when the abdominal pain had reduced. The patient's family was educated about the medicine and was recommended to be followed up in the pediatric gastro-hepatology polyclinic. The patient received omeprazole and ciprofloxacin when discharged.

Discussions

Gastrointestinal bleeding is frequently found in children. The condition is further divided into upper and lower gastrointestinal bleeding based on the injury site. In children, upper gastrointestinal bleeding is seen to occur more than lower gastrointestinal bleeding, with total incidents of 6.4% and 0.3%, respectively.^{3,4} The etiology and manifestation of gastrointestinal bleeding may vary depending on the age and location of the bleeding. Among children aged 2-5 years old, the differential diagnosis of upper gastrointestinal bleeding includes erosive esophagitis, esophageal varices, gastritis, gastric ulcer, and vomit-induced bleeding. The commonly found manifestation of upper GI bleeding includes melena (dark, tarry, stool).³ However, melena may also be found in the small intestine and ascending colon bleeding.

In contrast, lower gastrointestinal bleeding is frequently caused by polyps, intussusception, Meckel's diverticulum, infectious enterocolitis, and anal fissure. In this type of bleeding, the manifestation is frequently appeared as hematochezia (fresh

blood through the anal).^{5,6} In our case, the patient presented with dark, bloody stool, pallor, abdominal pain, and nausea. According to the explanation above, we concluded that the patient might suffer from esophageal until ascending colon bleeding.

Among children aged 2-5 years old, one of the most common etiologies of lower gastrointestinal bleeding is polyp. The condition is further classified into several categories, which are juvenile polyps, inherited hamartomatous polyposis syndromes, inherited adenomatous polyposis syndromes, and non-inherited polyposis. The manifestation of polyps may vary, including abdominal pain and melena. In particular, melena is more prevalent in the cases of polyposis syndrome. The diagnosis of polyps is made through endoscopy and colonoscopy. The diagnosis is further confirmed through biopsy, which is essential to differentiate the type of polyps.^{7,8} In our case, the patient is showing recurrent hospitalization due to bloody stool and a family history of similar condition. This might indicate that the condition is an inherited disorder.

During the physical examination, anemic conjunctiva, multiple black spots on the lips and buccal mucosa (melanotic macules), and epigastric tenderness were found in this patient. Evaluation using endoscopy and colonoscopy examination was then conducted to locate the gastrointestinal bleeding. Through the examination, multiple polyposis, scar ulcers in the duodenal region, and erosive inflammation along the GI tract were found. These findings supports the suspicion towards PJS.

PJS patients were at approximately 37-93% increased risk of developing malignancy.^{8,9} Peutz-Jeghers Syndrome is caused by the mutation of embryonic cells in the STK11 tumor suppressor gene.⁷ Typical pigmentations, small blackish macules measuring 1–5 mm, are commonly seen around the corners of the lips and may extend to the buccal mucosa. These macules can also be found on the hands, feet, and genital area and may fade over time with age.^{8,9}

In the case of PJS, polyps were commonly found in the small intestine (64%), followed by colon (53%), stomach (49%), and rectum (32%). This is in accordance with our patient, who displayed the presence of polyps in gaster, small intestine, large intestine, and rectum. The number of PJS polyps is usually low (20 polyps), and their diameter ranges from a few millimeters to more than 5 cm. The polyp is usually a hamartomatous polyp.⁹

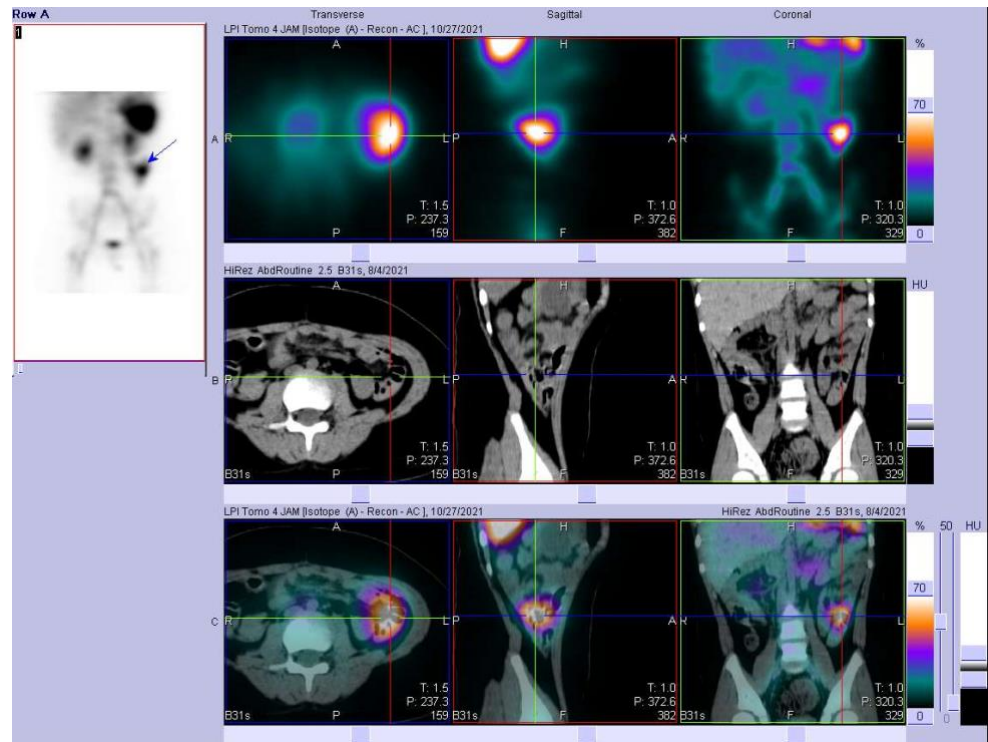


Figure 3. Scintigraphy: signs of upper gastrointestinal bleeding in the pylorus of the stomach and lower gastrointestinal bleeding in the middle part of the descending colon were found.

PJS is diagnosed if one of the following conditions is found: (a) two or more histologically confirmed PJS hamartomatous polyps; (b) any number of PJS polyps and has a family history of PJS; (c) PJS polyps with the characteristic of mucocutaneous pigmentation; (d) characteristic pigmentation combined with a family history of PJS. Meanwhile, on the physical examination, pigmentation of the lip mucosa is the most prominent feature.¹⁰ Based on this knowledge, the patient had met the diagnostic criteria for PJS. Hence, biopsy and scintigraphy were planned to establish the diagnosis and find other sources of bleeding in the abdomen cavity. Despite not being done in this study, we also recommend further examination using molecular genetic testing to identify the mutation of embryonic cells in the STK11 tumor suppressor gene, as the syndrome is caused by the mutation in this particular suppressor gene.^{1,7}

The histopathological features of PJS polyps are unique; their smooth muscle proliferation extends to the lamina propria with a pattern resembling a tree branch and extends to the mucosal surface of the polyp.⁹ In our case, hyperplastic polyps in the fundus, corpus, antral, ileocecal, terminal ileal, transverse colon, sigmoid colon, and rectum were found in the patient's biopsy sample.

PJS patients are at approximately 37-93% increased risk of developing malignancy.^{8,9} The most commonly reported disease is colorectal carcinoma, followed by the breast, small intestine, gastric, pancreatic, gynecology, lung, and esophagus.⁸ Appendix cancer was reported in an adult patient with PJS in Japan.¹¹ Thus, malignancy screening is essential and should be included in the PJS treatment planning. During hospitalization, the GI bleeding in this patient got worsening. The patient was planned for surgical bleeding control with combined colonoscopy and laparotomy exploration. Unfortunately, after explaining and educating about the condition, the patient's family objected the plan. The patient was discharged after the abdominal pain relieved, and was recommended for routine control in the polyclinic

Conclusion

Gastrointestinal bleeding in children over one year of age is commonly caused by polyps with clinical manifestations of hematochezia and melena as found in this patient. There are various types of polyps in the child's age group, one of which is the PJS, characterized by mucocutaneous pigmentation as found in this patient. In particular, this patient also has a family history of similar complaints. Periodic evaluation with upper and lower gastrointestinal endoscopy may be considered in these patients, considering the risk of malignancy in PJS.

References

1. Daniell J, Plazzer JP, Perera A, Macrae F. An exploration of genotype-phenotype link between Peutz-Jeghers syndrome and STK11: a review. *Familial Cancer*. 2018;17(3):421-427.
2. Achatz MI, Porter CC, Brugières L, Druker H, Frebourg T, Foulkes WD, et al. Cancer Screening Recommendations and Clinical Management of Inherited Gastrointestinal Cancer Syndromes in Childhood. *Clinical Cancer Research*. 2017;23(13): e107-e114.
3. Owensby S, Taylor K, Wilkins T. Diagnosis and management of upper gastrointestinal bleeding in children. *J Am Board Fam Med*. 2015;28(1):134-45
4. Zahmatkeshan M, Fallahzadeh E, Najib K, Geramizadeh B. Etiology of Lower Gastrointestinal Bleeding in Children: A Single Center Experience from Southern Iran. *Middle East J Dig Dis* 2012;4:216-23.
5. Pillai RB, Tolia V. Gastrointestinal bleeding in infants and children. *Therapy*. 2008; 465-73.
6. Romano C, Oliva S, Martellosi S, Miele E, Arrigo S, Graziani MG, et al. Pediatric gastrointestinal bleeding : Perspectives from the Italian Society of Pediatric Gastroenterology. *World J Gastroenterol*. 2017; 23(8): 1328-37.
7. Macfarland SP, Zelle K, Katona BW, Wilkins BJ, Brodeur M, Mamula P. Gastrointestinal Polyposis in Pediatric Patients. *J Pediatr Gastroenterol Nutr*. 2020;69(3):273-80.
8. Kay M, Eng K, Wyllie R. Colonic polyps and polyposis syndromes in pediatric patients. *Curr Opin Pediatr*. 2015;27(5):634-41.
9. Huang SC, Erdman SH. Pediatric juvenile polyposis syndromes: an update. *Curr Gastroenterol Rep*. 2009;11(3):211-9.
10. McGarrity TJ, Amos CI, Baker MJ. Peutz-Jeghers Syndrome. In edition: Adam MP, Ardinger HH, Pagon RA, et al, editor. *GeneReviews*®. 2001 Feb 23 [Updated 2021 Sep 2].
11. Kurihara K, Suganuma T. Appendiceal cancer leading to intussusception detected incidentally during follow-up for Peutz-Jeghers syndrome. *Clin J Gastroenterol*. 2020;13(6):1136-43